

Opinion

Monkeypox and pregnancy: what do obstetricians need to know?

A. Khalil^{1,2*}, A. Samara^{3,4}, P. O'Brien^{5,6}, E. Morris^{5,7}, T. Draycott^{5,8}, C. Lees⁹ and S. Ladhani^{10,11,12}

¹Fetal Medicine Unit, St George's University Hospitals NHS Foundation Trust, University of London, London, UK; ²Vascular Biology Research Centre, Molecular and Clinical Sciences Research Institute, St George's University of London, London, UK; ³Department of Women's and Children's Health, Karolinska Institute, Stockholm, Sweden; ⁴Astrid Lindgren Children's Hospital, Karolinska University Hospital, Stockholm, Sweden; ⁵The Royal College of Obstetricians and Gynaecologists, London, UK; ⁶University College London Hospitals NHS Foundation Trust, London, UK; ⁷Norfolk and Norwich University Hospitals NHS Foundation Trust, Norwich, Norfolk, UK; ⁸North Bristol NHS Trust Department of Women's Health, Westbury on Trym, UK; ⁹Imperial College London, London, UK; ¹⁰Paediatric Infectious Diseases Research Group and Vaccine Institute, Institute of Infection and Immunity, St George's University of London, London, UK; ¹¹Immunisation and Countermeasures Division, Public Health England; ¹²British Paediatric Surveillance Unit, Royal College of Paediatrics and Child Health, London, UK

*Correspondence. (e-mail: akhalil@sgul.ac.uk)

This article has been accepted for publication and undergone full peer review but has not been through the copyediting, typesetting, pagination and proofreading process which may lead to differences between this version and the [Version of Record](#). Please cite this article as doi: [10.1002/uog.24968](https://doi.org/10.1002/uog.24968)

Introduction

An outbreak of monkeypox affecting multiple countries began in early May 2022 and, as of 25 May 2022, a total of 219 confirmed cases have been reported worldwide, with case numbers continuing to rise rapidly¹. This is the first outbreak outside of Africa for which the source cannot as yet be directly traced back to west or central Africa, where this disease is endemic. Laboratory investigations have confirmed that the current outbreak is due to the west African clade of monkeypox²⁻⁴, which has a case fatality ratio of around 1%³. The central African (Congo Basin) clade has historically caused more severe disease and may also be more transmissible, with a case fatality rate of up to 10%.

Epidemiology

The monkeypox virus belongs to the orthopoxvirus genus and was first identified in monkeys in 1958⁵. The orthopoxvirus genus includes, among others, the variola virus (causing smallpox), vaccinia virus (used in the smallpox vaccine) and the cowpox virus. In spite of its name, the main host of monkeypox is rodents and its natural reservoir remains unknown. The first human case of monkeypox was recorded in 1970 in the Congo. Since then, monkeypox has become endemic in west and central Africa; the majority of cases are reported in the Democratic Republic of the Congo (DRC), with thousands of cases annually⁶.

The last naturally occurring case of smallpox occurred in Somalia in 1977, following the worldwide vaccination program to eradicate the disease. Consequently, the smallpox vaccine was discontinued in the late 1970s. The significant cross-protection that this vaccine offered against monkeypox has, therefore, been lost, and the monkeypox virus has become a more significant pathogen among humans. A large monkeypox outbreak that started in Nigeria in 2017 and continues to this day, has crossed Nigeria's borders eight times, with infected people carrying the virus to a number of countries, including the UK and the USA⁷.

Incubation and transmission

Transmission of the monkeypox virus to humans can occur via animal bite or direct contact with the blood, meat, bodily fluids or cutaneous/mucosal lesions of the infected animal. Human-to-human transmission by close direct contact and via exhaled large droplets is rare, but can occur sporadically. Sexual transmission may also be possible, although it is not clear if this is due to sexual contact or close contact during intercourse⁸. Although the evidence is limited and the risk of human-to-human transmission appears to be low, infants and young children appear to be at the greatest risk of severe disease.

Signs, symptoms and natural history

The extent to which asymptomatic monkeypox infection may occur is unknown. The incubation period is usually 6–13 days, but can range from 5 to 21 days. This is followed by a prodromal phase characterized by fever, sweats, headaches, myalgia and fatigue. The skin-eruption phase usually begins 1–3 days after the appearance of fever. The rash tends to affect the face and extremities, and it evolves from macules to papules, vesicles, pustules and eventually crusts (Figure 1). These lesions may resemble those of smallpox or chickenpox, but lymphadenopathy is usually more prominent in monkeypox infection^{9,10}. Immunocompromised individuals are vulnerable to more serious disease and have a higher case fatality rate.

Monkeypox virus in pregnancy

There are very limited data on monkeypox infection in pregnancy, primarily due to the socio-economic challenges and civil strife in many countries in which it is endemic, meaning that reporting in the medical literature is rare. It is unclear if vertical transmission of monkeypox virus can occur. The World Health Organization (WHO) reports that transmission from the mother to the fetus can occur via the placenta (which can lead to congenital monkeypox) or by close contact during and after birth¹¹. An observational study of a cohort of 222 symptomatic individuals admitted to hospital with monkeypox in the DRC between 2007 and 2011 included four pregnant women¹². Three of the four women experienced fetal demise and the fourth delivered a healthy baby at term. The pregnancy losses included two women with moderate-to-severe disease that ended in spontaneous miscarriage in the first trimester; in both cases, testing of pregnancy tissue was not performed. The third woman had moderately severe monkeypox disease at 18 weeks' gestation and experienced an intrauterine fetal demise. The fetus had clinical features of monkeypox infection and there was virological, histological and serological evidence suggesting that the fetus died due to vertical transmission of this virus. Specifically, the fetus had diffuse cutaneous maculopapillary lesions on the skin of the head, trunk and extremities (including the abdomen, chest, back and also the palms and soles of the hands and feet). There was also hydrops fetalis and marked hepatomegaly with peritoneal effusion. There were no congenital malformations or deformities, or gross abnormalities in the placenta, placental membranes or umbilical cord. Extensive postmortem autolysis present was consistent with intrauterine fetal demise¹². In another report of a probable (non-laboratory-confirmed) case, a pregnant woman infected at around 24 weeks' gestation delivered a premature infant 6 weeks later. The baby had a generalized skin rash consistent with monkeypox disease and died of malnutrition 6 weeks later¹⁰.

Data on monkeypox in pregnancy are clearly limited and subject to reporting bias. There is currently no evidence on the risk of viral transmission to the infant during breastfeeding,

whether via the breast milk, direct contact with maternal skin lesions or via large droplet spread. Of note, the related orthopoxvirus smallpox is associated with an increased risk of maternal and perinatal morbidity and mortality, including fetal death, preterm birth and spontaneous miscarriage^{11,13,14}.

Diagnosis

If a pregnant person presents with symptoms suggestive of monkeypox (such as a rash or new genital lesions)¹⁵, doctors should include monkeypox infection in the differential diagnosis, regardless of whether the person has a history of travel to a central or west African country¹⁶. Monkeypox is diagnosed by polymerase chain reaction (PCR) testing of a viral swab, which can discriminate not only monkeypox virus from other orthopoxviruses but also between the central African and west African clades. Currently, there is no approved monkeypox virus assay, and positivity in most countries is confirmed by national reference laboratories¹⁷. On 25 May 2022, the pharmaceutical company Roche (Basel, Switzerland) announced that they have developed a quantitative-PCR-based detection kit for monkeypox virus¹⁸. The swab should preferably be taken from an open sore or the surface of a vesicle, then placed in a viral culture medium or viral transport medium to be sent to the virology laboratory¹⁹. If all lesions are crusted, scab material should be scraped into a dry plain universal container. If the patient has fever, a widespread rash, sore throat or other systemic symptoms, an EDTA blood sample and a throat swab should also be taken (throat swab should be sent in viral transport medium). For high-risk contacts of a confirmed case who have systemic symptoms but do not have a rash or lesions for sampling, a throat swab should be taken¹⁹. Scabs, swabs and aspirated lesion fluid are preferable to blood samples because of the limited duration of viremia, so if lesions are present, they should be prioritized for swabbing.

Personal protective equipment and isolation

Healthcare personnel should wear appropriate personal protective equipment (PPE) each time they are near suspected or confirmed cases of monkeypox and follow practices used for protection against airborne, droplet and contact viruses. This should include properly fitted FFP3 respirators, gloves, gown and eye protection, such as goggles or a face shield. Patients with suspected or PCR-confirmed monkeypox infection should be isolated in a negative pressure room. In some healthcare systems, once a diagnosis of monkeypox is confirmed, the patient will be transferred to a specialized center for further care. For example, in the UK, this would be a High-Consequence Infectious Diseases unit.

Antiviral therapy

Currently there is no specific medication to treat monkeypox, but the antiviral drugs cidofovir, brincidofovir and tecovirimat may be considered²⁰. Tecovirimat is approved by the US Food and Drug Administration (FDA) for the treatment of human smallpox disease in adults and children weighing at least 3 kg²¹. Tecovirimat has not been authorized for use during pregnancy, as there are no data around its use in pregnant women and animal studies are insufficient with respect to reproductive toxicity²². As prognosis depends on multiple factors, the current Centers for Disease Control and Prevention (CDC) guidance for treatment of monkeypox is that pregnant and breastfeeding women may be at high risk of severe disease and should therefore be considered for treatment following consultation with the CDC²¹. According to the FDA advice, an alternative therapy to brincidofovir should be used to treat smallpox during pregnancy, if feasible²³; the same advice presumably applies to its use for monkeypox. Cidofovir is categorized as a FDA pregnancy category C drug because embryotoxic and teratogenic effects were observed in animal studies, including small-for-gestational age and soft-tissue and skeletal abnormalities²⁴. The recommendation is that the use of this drug should be considered only when the woman is severely ill.

Immunoglobulin

During the 2003 monkeypox outbreak in the USA, the CDC issued guidance for the prevention of monkeypox using the smallpox vaccine or vaccinia immune globulin (VIG)²⁵. VIG is a cocktail of antibodies purified from the blood of individuals immunized with the smallpox vaccine. There are no available data on the effectiveness of VIG in the treatment of monkeypox; however, the CDC advise that it can be considered for prophylactic use when individuals exposed to monkeypox have severe immunodeficiency in T-cell function, in whom vaccination, which includes a live attenuated virus, would be contraindicated²⁶. Although little is known about VIG in pregnancy, other immunoglobulins have been studied extensively and generally found to be safe in pregnancy²⁴.

Immunization in the non-pregnant population

Although routine immunization for smallpox ended almost 50 years ago, older people vaccinated before then should still have protection against monkeypox. Moreover, as monkeypox is largely a self-limiting disease, healthy adults are expected to recover from the infection. Although the evidence is limited, children and infants appear to be at the greatest risk of severe disease²⁷.

Illness can be mitigated by post-exposure vaccination using MVA-BN[®], a third generation (live, non-replicating) vaccine. In the current monkeypox outbreak, the advice by the UK Health Security Agency (UKHSA; previously known as Public Health England)²⁸ and the CDC²⁹ is to vaccinate contacts of confirmed cases, including healthcare workers, ideally within 4 days and up to 21 days after exposure (i.e. post-exposure prophylaxis). Administration of the vaccine up to 14 days post-exposure may not prevent the disease but may reduce the severity of symptoms²⁹. MVA-BN generates protective immune response against a variety of orthopoxviruses, and is 85% effective in protecting against monkeypox²⁸.

Approved in 2013, MVA-BN is marketed in the European Union (EU) as Imvanex³⁰ and is the only third generation vaccine licensed for active immunization against smallpox in adults. The manufacturer (Bavarian Nordic, Martinsried, Germany) has not yet sought an EU licence extension to include immunization against monkeypox. In the USA, however, where MVA-BN is marketed as JYNNEOS[™], it is approved by the FDA for vaccination against both smallpox and monkeypox infection in adults³¹.

Immunization in pregnancy

Currently there is no approved vaccine against monkeypox for use in pregnancy. Data are available for the MVA-BN vaccine in fewer than 300 pregnant women and no increase in adverse pregnancy outcomes was noted³². As MVA-BN is a non-replicating virus vaccine, there is no theoretical basis for concern about its use in pregnancy. Animal studies (three studies in female rats) did not find any direct or indirect adverse fetal effects related to the vaccine²⁸. Currently, the general advice is that, while MVA-BN is not contraindicated in pregnancy, as a precautionary measure, its use should be avoided during pregnancy unless it is considered that the possible benefits (both fetal and maternal, especially those in the third trimester²⁸) in terms of preventing smallpox outweigh any potential unknown risk of the vaccine³².

In 2003 the USA began a national smallpox vaccination program in response to concerns about the potential use of biological weapons worldwide and set up the National Smallpox Vaccine in Pregnancy Registry to monitor the effects of inadvertent vaccination of pregnant women. Notably, between 2003 and 2006, vaccination near the time of conception or during pregnancy did not reveal higher than expected rates of pregnancy loss (11.9%), preterm birth (10.7%) or birth defects (2.8%) compared to national data³³. No cases of fetal vaccinia (a very rare condition, almost always after primary vaccination, in which the vaccinia virus has infected the fetus, usually fatally) have been identified.

MVA-BN is considered safe in breastfeeding²⁸ (as are other live vaccines, even those contraindicated during pregnancy). It is not known whether MVA-BN passes into the breast milk, but it is considered unlikely as the vaccine virus does not replicate effectively in humans. Any woman with a significant exposure to monkeypox virus should therefore be offered vaccination after birth, after consideration of the risks of monkeypox infection to her and her breastfeeding baby. A flowchart of proposed management of suspected monkeypox infection in pregnancy is shown in Figure 2.

Fetal surveillance

Because data on monkeypox infection in pregnancy are limited, the risk to the fetus is currently unquantifiable; however, it appears that vertical transmission and fetal demise are possible. Therefore, until more data are available, it would be wise to take a cautious approach in pregnancies with confirmed monkeypox infection. This would include regular (2–3 times daily) assessment of fetal wellbeing with cardiotocography, if the gestational age is ≥ 26 weeks or if the mother is unwell. Ultrasound assessment of the fetus and placental function should be performed regularly during the acute infection. In the first trimester, this would be to confirm viability and offer screening. In the second trimester, assessment should include fetal biometry 10–14 days apart, detailed anatomy scan and amniotic fluid volume measurement. In the third trimester, assessment should include fetal biometry 10–14 days apart, detailed anatomy scan, amniotic fluid volume measurement and fetal Doppler (umbilical artery and middle cerebral artery). It is likely that, once the maternal infection has resolved, the risk to the fetus is small; however, again, as data are limited, 4-weekly fetal scans for the rest of the pregnancy should be considered, as a precaution. A flowchart of proposed management of pregnancies with confirmed monkeypox infection is shown in Figure 3.

Timing and mode of delivery

In general, maternal monkeypox infection *per se* is not an indication to expedite delivery, as most cases are not serious and are self-limiting, particularly those caused by the west African clade of the virus responsible for the current outbreak. If at any stage there is evidence of fetal compromise, or if the life of the mother is at risk, consideration should be given to delivering the baby, taking into account the gestational age, estimated fetal weight, condition of the fetus, and whether the mother is likely to benefit from, or be further compromised by, the birth (generally Cesarean section in these circumstances). Magnesium sulfate should be administered for neonatal neuroprotection when preterm delivery is contemplated, in line with unit policy. It seems unlikely that a single course of steroids for fetal maturation prior to preterm birth would have a significant adverse effect on the maternal condition. However, their planned

use should be discussed with the virologist and the wider multidisciplinary team caring for the woman.

There is no evidence around the optimal mode of delivery in a woman with active monkeypox infection. It is likely that vertical transmission is possible, so the baby may already be infected before birth, in which case Cesarean section may be of no benefit. It is known that the virus can be transmitted via contact with open monkeypox lesions. It is likely, therefore, that labor and/or vaginal birth in a woman with genital lesions may lead to neonatal infection. Given that infants appear to be at the greatest risk of severe monkeypox infection, if genital lesions are identified, Cesarean section should be recommended. Even if genital lesions cannot be identified in a woman with confirmed or likely monkeypox infection, Cesarean section should be offered following discussion of the (currently unquantifiable) risk of neonatal infection, which may be serious. A proposed management of suspected or confirmed monkeypox infection in labor or if urgent delivery is needed is shown in Box 1.

Neonatal care

There is little evidence to guide neonatal care following the birth of a baby to a woman with monkeypox infection. Apart from macroscopic examination, the baby should undergo viral PCR testing either by throat swab or any lesions that are present. The baby should be isolated at birth from its mother and others, in a single room, with carers wearing appropriate PPE. The baby should be carefully monitored for signs of compromise or monkeypox infection. If the baby tests positive, the mother and baby can be reunited. Ideally, both mother and baby should be tested in parallel thereafter; after the mother is de-isolated (e.g. two negative PCR tests), mother and baby should be reunited. If a mother has reached a threshold to warrant PCR testing for the monkeypox virus, the baby should be isolated pending her swab result.

Breastfeeding

The proposed strategy for neonatal care would preclude most women with active monkeypox infection from breastfeeding their newborn. The WHO advises against breastfeeding; this seems reasonable in high-income country settings, such as the UK, in order to minimize the risk of neonatal monkeypox infection. However, in low- and middle-income countries the benefits of breastfeeding may outweigh the potentially increased risk of neonatal monkeypox infection.

Reporting

Little is known about the effects of monkeypox infection in pregnancy, and it is essential that this opportunity to learn and improve care is not squandered. An international registry of cases

in pregnant women and other vulnerable individuals should be set up without delay. All obstetricians should strive to report cases so that, armed with greater knowledge, future outbreaks can be tackled more effectively. This becomes increasingly important as international borders blur with increased transport of both humans and animals, so the threat of infectious disease outbreaks with new and unusual pathogens continues to grow.

References

1. <https://www.ecdc.europa.eu/en/news-events/epidemiological-update-monkeypox-multi-country-outbreak>
2. <https://www.gov.uk/government/news/monkeypox-cases-confirmed-in-england-latest-updates>
3. <https://virological.org/t/first-draft-genome-sequence-of-monkeypox-virus-associated-with-the-suspected-multi-country-outbreak-may-2022-confirmed-case-in-portugal/799>
4. <https://nextstrain.org/monkeypox?c=country&p=grid>
5. Centers for Disease Control and Prevention. <https://wwwnc.cdc.gov/travel/notices/alert/monkeypox>
6. Centers for Disease Control and Prevention. <https://www.cdc.gov/poxvirus/monkeypox/index.html>
7. Beer EM, Rao VB. A systematic review of the epidemiology of human monkeypox outbreaks and implications for outbreak strategy. *PLoS Negl Trop Dis* 2019; **13**: e0007791.
8. World Health Organization. Monkeypox - United Kingdom of Great Britain and Northern Ireland. <https://www.who.int/emergencies/disease-outbreak-news/item/2022-DON381>
9. Marennikova SS, Shelukhina EM, Matsevich GR, Ezek Z, Khodakevich LN, Zhukova OA, Yanova NN, Chekunova EV. Monkey pox in humans: current results. *Acta Virol* 1989; **33**: 246–253.
10. Jezek Z, Gromyko AI, Szczeniowski MV. Human monkeypox. *J Hyg Epidemiol Microbiol Immunol* 1983; **27**: 13–28.
11. World Health Organization. Monkeypox. <https://www.who.int/news-room/fact-sheets/detail/monkeypox>
12. Mbala PK, Huggins JW, Riu-Rovira T, Ahuka SM, Mulembakani P, Rimoin AW, Martin JW, Muyembe JT. Maternal and Fetal Outcomes Among Pregnant Women With Human Monkeypox Infection in the Democratic Republic of Congo. *J Infect Dis* 2017; **216**: 824–828.
13. Constantin CM, Martinelli AM, Foster SO, Bonney EA, Strickland OL. Smallpox: a disease of the past? Consideration for midwives. *J Midwifery Womens Health* 2003; **48**: 258–267.
14. Waterson AP. Virus infections (other than rubella) during pregnancy. *Br Med J* 1979; **2**: 564–566.
15. Centers for Disease Control and Prevention. <https://www.cdc.gov/poxvirus/monkeypox/clinicians/clinical-recognition.html>
16. Centers for Disease Control and Prevention. <https://www.cdc.gov/poxvirus/monkeypox/clinicians/index.html>
17. ECDC. Monkeypox multi-country outbreak. <https://www.ecdc.europa.eu/sites/default/files/documents/Monkeypox-multi-country-outbreak.pdf>

18. <https://www.roche.com/media/releases/med-cor-2022-05-25>
19. <https://www.gov.uk/guidance/monkeypox-diagnostic-testing>
20. Centers for Disease Control and Prevention.
<https://www.cdc.gov/poxvirus/monkeypox/clinicians/treatment.html#Tecovirimat>
21. What Clinicians Need to Know About Monkeypox in the United States and Other Countries Clinician Outreach and Communication Activity (COCA) Call Thursday, May 24, 2022. https://emergency.cdc.gov/coca/ppt/2022/052422_slides.pdf
22. European Medicines Agency. Assessment report. Tecovirimat SIGA.
https://www.ema.europa.eu/en/documents/assessment-report/tecovirimat-siga-epar-public-assessment-report_en.pdf
23.
https://www.accessdata.fda.gov/drugsatfda_docs/label/2021/214460s000,214461s000lbl.pdf
24. Centers for Disease Control and Prevention. Updated interim CDC guidance for use of smallpox vaccine, cidofovir, and vaccinia immune globulin for prevention and treatment in the setting of an outbreak of monkeypox infections.
25. Centers for Disease Control and Prevention. Interim guidance for use of smallpox vaccine, cidofovir, and vaccinia immune globulin (VIG) for prevention and treatment in the setting of outbreak of monkeypox infections. Atlanta, 2003.
<https://stacks.cdc.gov/view/cdc/25058>
26. <https://www.cdc.gov/poxvirus/monkeypox/clinicians/treatment.html#vig>
27. Yinka-Ogunleye A, Aruna O, Dalhat M, Ogoina D, McCollum A, Disu Y, Mamadu I, Akinpelu A, Ahmad A, Burga J, Ndoreraho A, Nkunzimana E, Manneh L, Mohammed A, Adeoye O, Tom-Aba D, Silenou B, Ipadeola O, Saleh M, Adeyemo A, Nwadiutor I, Aworabhi N, Uke P, John D, Wakama P, Reynolds M, Mauldin MR, Doty J, Wilkins K, Musa J, Khalakdina A, Adedeji A, Mba N, Ojo O, Krause G, Ihekweazu C; CDC Monkeypox Outbreak Team. Outbreak of human monkeypox in Nigeria in 2017-18: a clinical and epidemiological report. *Lancet Infect Dis* 2019; **19**: 872–879.
28. UK Health Security Agency. Recommendations for the use of pre and post exposure vaccination during a monkeypox incident. 2022.
https://assets.publishing.service.gov.uk/government/uploads/system/uploads/attachment_data/file/1080615/Recommendations-for-pre-and-post-exposure-vaccination-during-a-monkeypox-incident-1-june-2022.pdf
29. Centers for Disease Control and Prevention. Monkeypox and Smallpox Vaccine Guidance. 2019. [Monkeypox and Smallpox Vaccine Guidance | Monkeypox | Poxvirus | CDC](#)
30. <https://www.ema.europa.eu/en/medicines/human/EPAR/imvanex>
31. <https://www.fda.gov/vaccines-blood-biologics/jynneos>
32. European Medicines Agency. Bavarian Nordic. Summary of Product Characteristics. 2019.
33. Ryan MA, Seward JF; Smallpox Vaccine in Pregnancy Registry Team. Pregnancy, birth, and infant health outcomes from the National Smallpox Vaccine in Pregnancy Registry, 2003-2006. *Clin Infect Dis* 2008; **46** (Suppl 3): S221–226.

FIGURE LEGENDS

Figure 1 Monkeypox rash.

Figure 2 Proposed management of suspected monkeypox infection in pregnancy.

*Recommended personal protective equipment (PPE): FFP3 face mask, eye protection, disposable water repellent, long sleeved gown, gloves. All waste should remain in the room until patient confirmed negative.

Figure 3 Proposed management of confirmed monkeypox infection in pregnancy. CTG, cardiotocography; GA, gestational age; MCA, middle cerebral artery; PCR, polymerase chain reaction; UA, umbilical artery.

Box 1 Proposed management of suspected or confirmed monkeypox infection in labor or if urgent delivery is needed. NNU, neonatal unit; PPE, personal protective equipment.

Figure 1

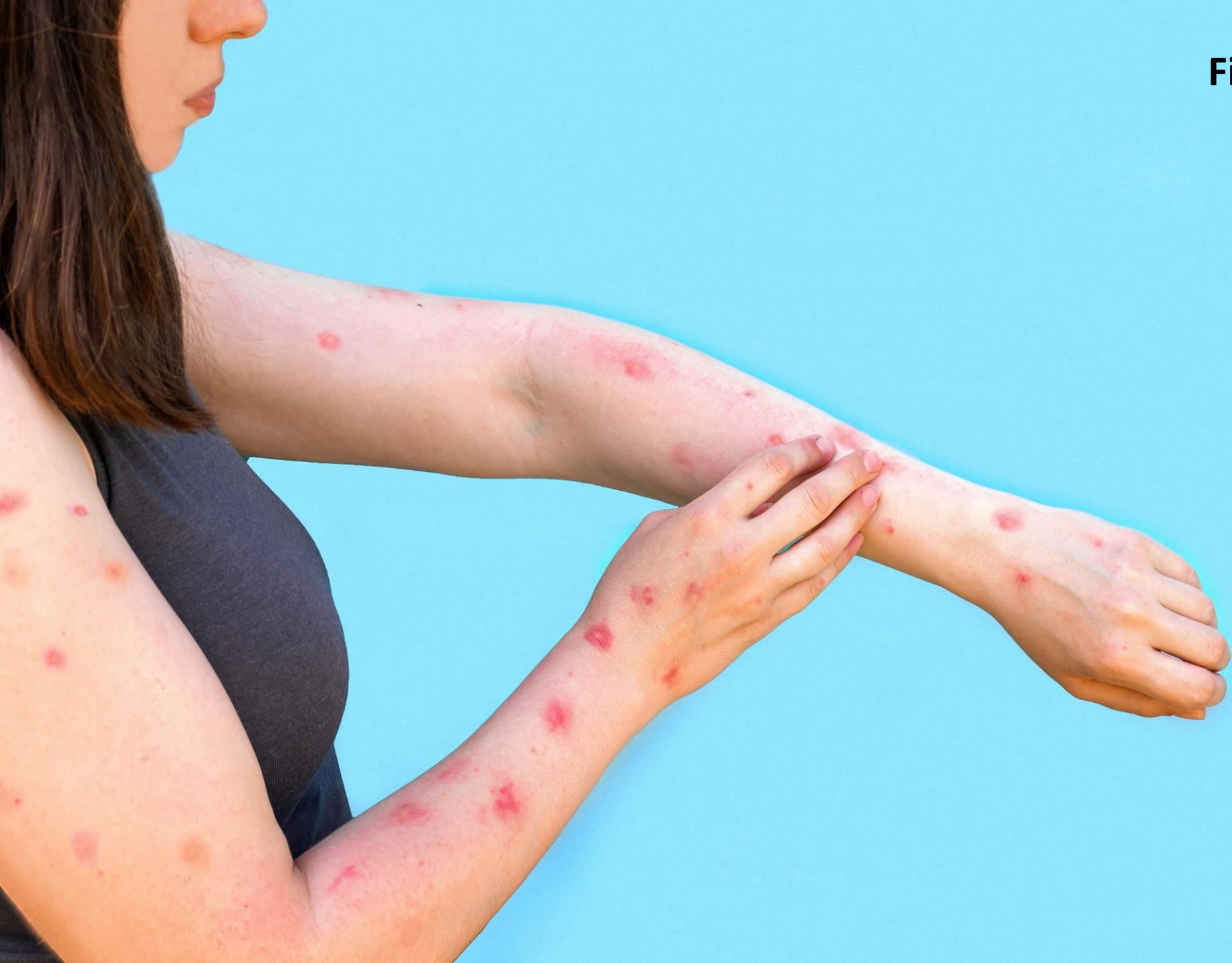

Figure 2

Unexplained rash on any part of the body

AND

One or more classical symptom(s) of monkeypox infection: fever $>38.5^{\circ}\text{C}$, intense headache, arthralgia, backache or lymphadenopathy,

AND either:

- Epidemiological link to a confirmed or probable case of monkeypox in the 21 days before symptom onset (consider sexual transmission)

OR

- Reported a travel history to west or central Africa in the 21 days before symptom onset



Mask patient and isolate in a side room



Obstetrician to assess and contact consultant virologist
Staff to wear PPE*



- Discuss with virologist testing needed; follow guidance regarding sampling (viral swab for PCR from lesions or throat, or blood sample depending on clinical presentation)
- Minimize contact with vulnerable staff (pregnant/immunosuppressed)

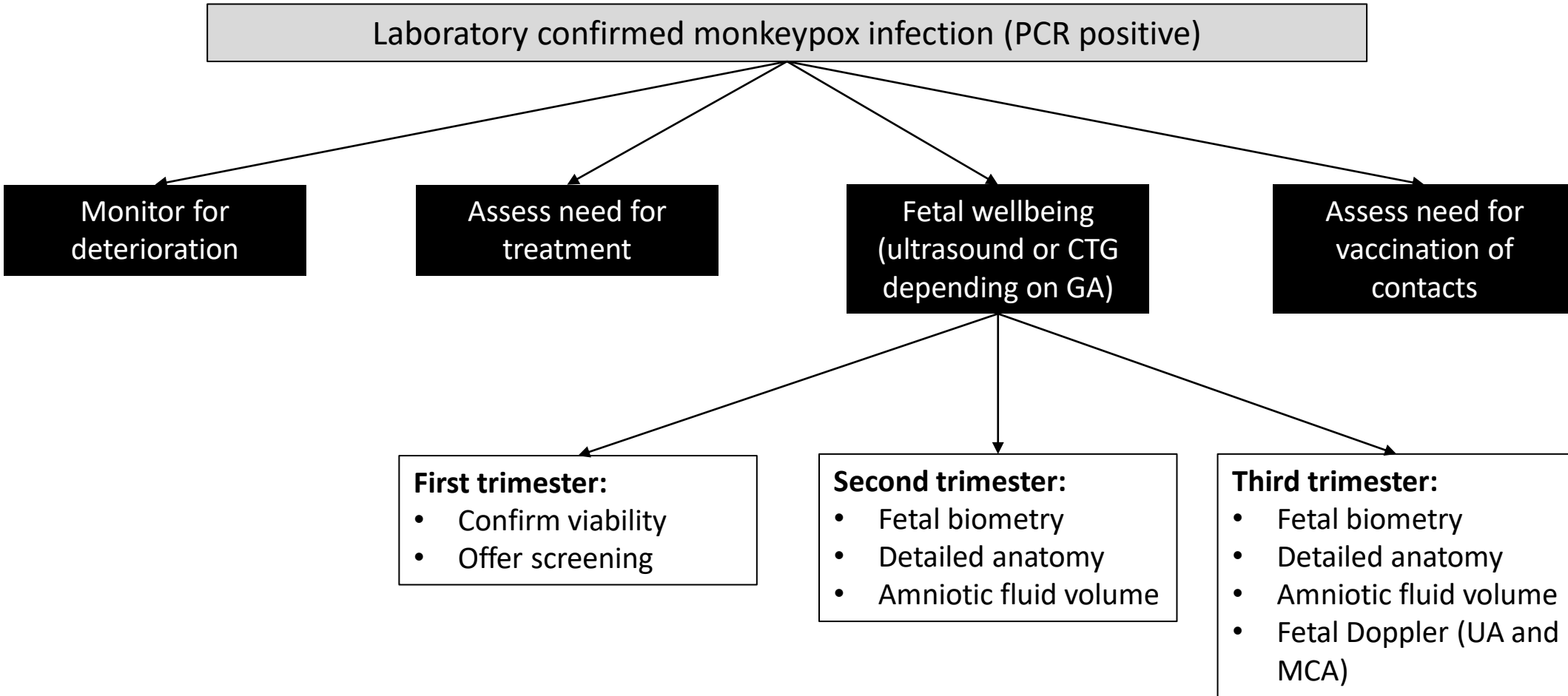
Admission NOT needed

- Discharge home to self-isolate
- Ask patient to wear mask and cover exposed skin on way home
- Ask patient to refrain from sex or intimate contact
- Follow-up contact

Admission needed

- Requires urgent/acute maternity care: remain in maternity area, obstetric care and isolate
- Needs admission, but does not require maternity care: admit to relevant ward
- Refer to virologist and relevant specialists

Figure 3



Box 1

- Advise delivery via Cesarean section
- Assess need for steroids and magnesium sulfate
- Maternity and neonatal staff to wear PPE
- Mother and baby should be isolated separately; avoid NNU admission if possible
- Mother should not breastfeed
- Encourage expressing so mother has opportunity to breastfeed after de-isolation; follow recommendations for pump cleaning after each use
- Milk should be discarded as infected waste*
- Discuss with virologist testing needed
- If mother is negative, these precautions can be lifted
- If maternal infection confirmed, baby to be isolated for 3 weeks
- If both mother and baby test positive, they can be reunited

* Waste management. Clinical team responsibilities: (1) Discard all waste into clinical waste bag, close the bag by 'swan neck' technique & secure with cable tie; (2) Place in second clinical waste bag and close as above. Place bags in Griff bin & store pending test results. Rapid Response team responsibilities: (1) Wipe down all surfaces with green Clinell universal wipes, discard wipes in clinical waste as above; (2) Then wipe down all surfaces with Peracide (dissolve 5 small or 3 large tablets in 1.25L warm water); (3) Discard cloths into clinical waste as above.